

## Isolation of *Mycobacterium abscessus* in a Patient with Cutaneous Abscess-Case Report

Martínez-Romero A<sup>1</sup>, Ortega-Sánchez JL<sup>2</sup>, Cervantes-Flores M<sup>5</sup>, Hernández-Herrera AD<sup>1</sup>, Hernández-González SI<sup>1</sup>, Alba-Romero JJ<sup>1,3,4</sup>

<sup>1</sup>División De Estudios De Posgrado E Investigación, Facultad De Ciencias Químicas (FCQ), Campus Gómez Palacio, Universidad Juárez Del Estado De Durango (UJED).

<sup>2</sup>Unidad Regional De Zonas Áridas, Universidad Autónoma Chapingo, Bermejillo.

<sup>3</sup>Laboratorio De Asesores Especializados De La Laguna.

<sup>4</sup>Sanatorio San José, Gómez Palacio.

<sup>5</sup>FCQ, Campus Durango, UJED, Durango, México.

---

**Abstract:** *Mycobacterium abscessus* is a Rapidly Growing Mycobacteria found mainly in patients with respiratory or cutaneous infections, but it rarely causes disseminated infections. In this case report patient, 65 years-old patient, masculine gender, slaughterhouse worker with granulomatous lesions, presenting olecranon bursal tophi and external face with distal cubital radial articulation and right carpal and first carpal tunnel is presented. Puncture was performed in the dorsal region of the carpal region and right olecranon region in order to carry out acid-fast bacilli, culture, pheno- and genotypification. We proceeded to Polymerase chain reaction for confirmation of *Mycobacterium abscessus*.

**Keywords:** Non-tuberculous mycobacteria, mycobacteriosis, opportunistic

---

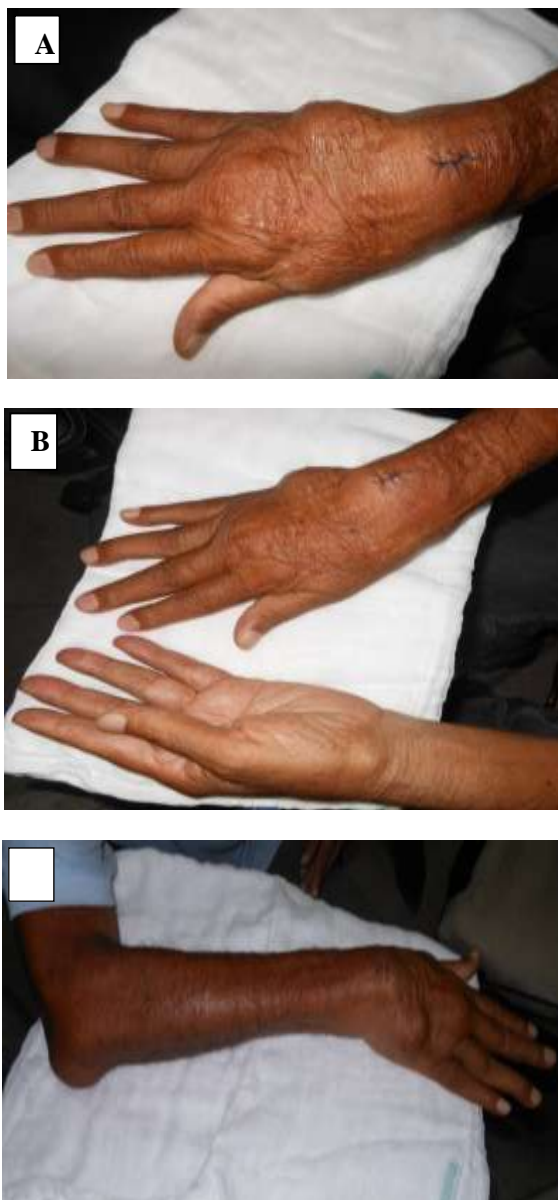
### I. Introduction

*Mycobacterium abscessus* is a Rapidly Growing Mycobacteria found mainly in patients with respiratory or cutaneous infections, but it rarely causes disseminated infections. The accepted term for infections caused by Non-tuberculous mycobacteria (NTM) is mycobacteriosis. Little is known about the clinical characteristics, treatment, and prognosis of disseminated *M. abscessus* infection[1]. *M. abscessus* is environmental microorganism that can be produced from colonization to disease in the susceptible host and that are commonly ingested, inhaled, or can be found in the skin. Diseases typically produced by *M. abscessus* are found associated with postsurgical infections, among which the following have been described: esthetic procedures such as mesotherapy or liposculptures, the appearance of abscesses after an injection; catheter-associated infections; and disseminated cutaneous, pulmonary, and central nervous system diseases that affect children and adults infected with the human immunodeficiency virus. *M. abscessus* is directly associated with patients with lacerated skin and lymphadenitis processes, member of the group of non-pigmented rapidly growing mycobacteria (RGM) 48-96 h, which develops at an optimal temperature of 37°C, resistant to treatment for tuberculous mycobacteria and, among other factors, the formation is found of a biofilm that permits its persistence[2-3].

Additionally, there is an important association between the presence of tuberculous and non-tuberculous mycobacteria and the presence of non-vaccine anti-TB antibodies, which can be utilized as an auxiliary tool with stains, cultures, and tests such as for phenotype as well as for genotype. This will consequently render efficiency in diagnosis and greater promptness, resulting in the correct treatment.

### II. Case Report

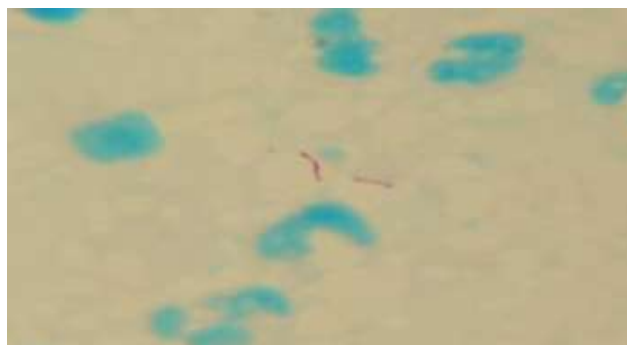
The present study was conducted in the nodule secretion of a patient of masculine gender aged 65 years, with granulomatous lesions with a diagnosis of gout, presenting olecranon bursal tophi and the external face with lysis of the distal cubital radial articulation and right carpal and first carpal tunnel, with a disease evolution of 4.5 years. The slaughterhouse worker initially refers a lesion with the bone of a pig. The lesion has been treated as "tophi", confusing his abscesses with gouty tophi, with the corresponding treatment (Fig. 1).



**Figure 1 A, B, and C:** Atypical cutaneous lesions, due to infection by *Mycobacterium abscessus*, confused with gouty tophi (abscesses).

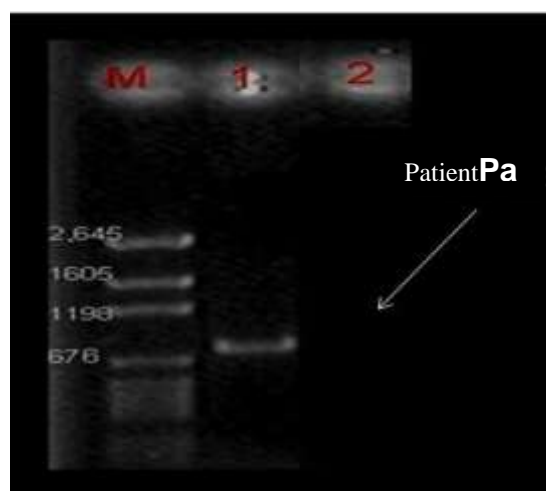
### III. Procedure

Laboratory findings and clinical signs showed: leukocytes  $17 \cdot 10^3/\mu\text{L}$  (reference range  $6-10 \cdot 10^3/\mu\text{L}$ ); uric acid 8.8 mg/dL (4.5-8.0 mg/dL); T/A 170/100; temperature  $37.5^\circ\text{C}$ , and cardiac frequency 85 sec, the patient referring having undergone clinical pneumonia condition. The clinical characteristics of the patient's lesions were as follows: pain; erythematous nodule; abscess; reddening; tumoration, and lymph node enlargement. To perform a differential diagnosis, aspiration was carried out by means of diagnostic puncture in the dorsal carpal region and in the right olecranon region with the purpose of obtaining liquid from the nodule's secretion for carrying out culture and Ziehl-Neelsen (ZN). Venous blood was also extracted for performing determination of non-vaccine anti-TB antibodies. Puncture was performed of the nodules, and Acid-Fast Bacillus (AFB) was carried out with a smear stained with the ZN method. Determination of non-vaccine anti-TB antibodies was positive. Puncture was performed of the nodules, and BAAR was carried out with a smear stained with the ZN method (Fig. 2). Tests for phenotypical identification included the following: niacin; thermostable catalase at  $68^\circ\text{C}$ ; nitrite reduction; Tween 80 hydrolysis test; urease, and the arylsulfatase test. The samples were decontaminated by the method of Petroff (NaOH solution at 4%), [4] and were concentrated and seeded in Middlebrook 7H10 agar medium (BD) and in Löwenstein-Jensen (LJ) conventional culture medium. Likewise, we proceeded to culture the reference strains by duplicate. Middlebrook 7H9 broth (BD) was utilized for the logarithmic phase [5].



**Figure 2:** The result of the bacilloscopy obtained from the sample of our patient.

On culturing this in Agar Middlebrook 7H10, the development was observed of small mycobacteria-like colonies. In LJ, *Mycobacterium*-like typical growth was achieved on day 3, with colonies white-to-cream-colored colonies, some with pigmentation, and a *Mycobacterium* genus-like granular aspect. This was confirmed by Gram and ZN staining and the isolate was later genotyped as *M. abscessus* by 16S DNA PCR and sequencing analysis [6]. In Figure 3, we are able to observe the amplified fragments to identify the genus *Mycobacterium* corresponds to the gene *murA*, the multiple hypervariable region, and the gene 16S 934pb, primers to identify the genus *Mycobacterium* (RAC) comprised RAC1 5'TCG ATG ATC ACC GAG AAC GTG TTC 3' and RAC8 5'CAC TGG TGC CTC CCG TAGG 3'; this sequence amplifies a fragment of 934 pb corresponding to the gene *murA*, the HVR, and the gene 16S rRNA. Empiric treatment was started with amikacin (i.m. 500 mg/t.i.d.) and oral clarithromycin (500 mg/b.i.d.) referring frank recovery, with diminution in abscess size, without the detection of recurrent abscesses.



**Figure 3:** Identification of the genus *Mycobacterium*. Amplification corresponds to the gene *murA*, the multiple hypervariable region, and the gene 16S 934pb.

#### IV. Discussion

The patient acquired the infection with *M. abscessus* on injuring himself with the bone of a pig on engaging in his occupational activities with contaminated water. In this respect, Harada reported that due to the high distribution of *M. abscessus* in nature, its main reservoirs comprise soil, foods, animals, and currents of water that causes infections of existential origin [7]. In addition, in relation to the case treated in that investigation, cases are described by *M. abscessus*-associated with otitis media, these are related with the use of contaminated water after washing of material such as tubes, obtaining the infection in cases of tympanostomy or due to skin abrasions, surgical incisions, and the use of contaminated central venous catheters [8]. Similarly, *M. abscessus* has been isolated in patients with cystic fibrosis with severe pulmonary infection [9].

For mycobacteria identification, primers were utilized that permitted amplification of the fragments corresponding to the genus, as well as those on that determining that the fragment concerned a *Mycobacterium* different from *Mycobacterium tuberculosis* Complex, and the species determined by phenotypical methods. In this way, this was identified as *M. abscessus*, whose genotypification was previously reported [10,11]. In an outbreak of *M. abscessus* infection after acupuncture that involved 109 patients, the infectious source was the glutaraldehyde solution that has been employed as disinfectant [10]. It was also reported that, due to *M.*

*abscessus*-associated infection caused by acupuncture procedures, the treatment utilized was the combination of clarithromycin and moxifloxacin with good clinical response [12]. In Mexico, NTM species were recovered from samples of water including drinking water and potable water accessed in households [13]. However, this study is the first to identify and classify *M. abscessus* directly in clinical patient sample with granulomatous lesions detected by molecular method. The isolation and identification of *M. abscessus* was achieved by means of geno- and phenotypification of the clinical sample of a patient from the Comarca Lagunera of Durango. AFB was evidenced through lesion puncture and bacilloscopy. Determination of non-vaccine anti-TB antibody determination was positive. The presence was confirmed of NTM in the infectious process of the skin; the recommendation is made to implement the search for skin lesions to discard the presence of NTM, in order to provide the patient with his treatment-of-choice.

## V. Conclusion

In this paper, we report a clinical case on *M. abscessus*. This is significant because mycobacteriosis this directly associated with patients is case rare or unusual. This case illustrates the pathogenic potential of RGM in medical or non-medical skin penetrating procedures and their world-wide distribution. *M. abscessus* was identified with *primers* that allowed the amplification of a fragment of 488 pb. Our patient developed clarithromycin and amikacin recovery.

## Acknowledgements

The authors would like to thank Maggie Brunner for English reviewing of the manuscript.

## References

- [1]. Fukui S, Sekiya N, Takizawa Y, Morioka H, Kato H, Aono A, et al. Disseminated *Mycobacterium abscessus* Infection Following Septic Arthritis: A Case Report and Review of the Literature. *Medicine (Baltimore)* 2015;94:e861.
- [2]. Koh WJ, Jeon K, Lee NY, Kim BJ, Kook YH, Lee SH, et al. Clinical significance of differentiation of *Mycobacterium massiliense* from *Mycobacterium abscessus*. *Am J Respir Crit Care Med* 2011;183:405-410.
- [3]. Stout JE, Floto RA. Treatment of *Mycobacterium abscessus*: all macrolides are equal, but perhaps some are more equal than others. *Am J Respir Crit Care Med* 2012;186:822-823.
- [4]. Organización Panamericana de la Salud y Organización Mundial de la Salud: Manual de para el diagnóstico bacteriológico de la tuberculosis. Normas y Guía técnica. OPS/OMS 2008.
- [5]. Akyar I, Kocagoz T, Sinik G, Oktem S, Aytekin N, Kocagoz S. Lateral flow assay for rapid differentiation of *Mycobacterium tuberculosis* complex and 97 species of mycobacteria other than tuberculosis grown in Lowenstein-Jensen and TK-SLC medium. *Indian J Med Microbiol* 2010;28:308-312.
- [6]. Cobos-Marin L, Montes-Vargas J, Rivera-Gutierrez S, Licea-Navarro A, González-y-Merchand JA, Estrada-García I. A novel multiplex-PCR for the rapid identification of *Mycobacterium bovis* in clinical isolates of both veterinary and human origin. *Epidemiol Infect* 2003;130:485-490.
- [7]. Harada T, Akiyama Y, Kurashima A, Nagai H, Tsuyuguchi K, Fujii T, et al. Clinical and microbiological differences between *Mycobacterium abscessus* and *Mycobacterium massiliense* lung diseases. *J Clin Microbiol* 2012;50:3556-3561.
- [8]. Caminero-Luna JA. Micobacterias atípicas. *BSCP Can Ped* 2001;25:237-248.
- [9]. Bernut A, Herrmann JL, Kissa K, Dubremetz JF, Gaillard JL, Lutfalla G, et al. *Mycobacterium abscessus* cording prevents phagocytosis and promotes abscess formation. *Proc Natl Acad Sci* 2014;111: E943-E952.
- [10]. Koh SJ, Song T, Kang YA, Choi JW, Chang KJ, Chu CS, et al. An outbreak of skin and soft tissue infection caused by *Mycobacterium abscessus* following acupuncture. *Clin Microbiol Infect* 2010;16:895-901.
- [11]. Al-Mahruqi SH, van Ingen J, Al-Busaidy S, Boeree MJ, Al-Zadjali S, Patel A, et al. Clinical relevance of nontuberculous Mycobacteria, Oman. *Emerg Infect Dis* 2009;15:292-294.
- [12]. Choi WS, Kim MJ, Park DW, Son SW, Yoon YK, Song T, et al. Clarithromycin and Amikacin vs. Clarithromycin and Moxifloxacin for the treatment of post-acupuncture cutaneous infections due to *Mycobacterium abscessus*: a prospective observational study. *Clin Microbiol Infect* 2011;17:1084-1090.
- [13]. Pérez-Martínez I, Aguilar-Ayala DA, Fernández-Rendón E, Carrillo-Sánchez AK, Helguera-Repetto AC, Rivera-Gutiérrez S, et al. Occurrence of potentially pathogenic nontuberculous mycobacteria in Mexican household potable water: a pilot study. *BMC Res Notes* 2013;6:531.